Eur Radiol (2015) 25:2859–2868
DOI 10.1007/s00330-015-3686-3

HEPATOBILIARY-PANCREAS

Noninvasive diagnosis of hepatocellular carcinoma on gadoxetic acid-enhanced MRI: can hypointensity on the hepatobiliary phase be used as an alternative to washout?

Ijin Joo · Jeong Min Lee · Dong Ho Lee · Ju Hyeon Jeon · Joon Koo Han · Byung Ihn Choi

Received: 29 August 2014 / Revised: 3 January 2015 / Accepted: 19 February 2015 / Published online: 14 March 2015
© European Society of Radiology 2015

Abstract
Objectives To determine which dynamic phase(s) of gadoxetic acid-enhanced MRI is most appropriate to assess "washout" in the noninvasive diagnosis of hepatocellular carcinoma (HCC) based on hemodynamic pattern.
Methods In this retrospective cohort study, 288 consecutive patients with chronic liver disease presented with 387 arterially enhancing nodules (292 HCCs, 95 non-HCCs) (≥1 cm) on gadoxetic acid-enhanced MRI. All HCCs were confirmed by histopathology or by their typical enhancement pattern on dynamic liver CT. MR imaging diagnosis of HCC was made using criteria of arterial enhancement and hypointensity relative to the surrounding parenchyma (1) on the portal-venous phase (PVP), (2) on the PVP and/or transitional phase (TP), or (3) on the PVP and/or TP, and/or hepatobiliary phase (HBP).
Results For the noninvasive diagnosis of HCC, criterion 1 provided significantly higher specificity (97.9 %; 95 % confidence interval, 92.6 – 99.7 %) than criteria 2 (86.3 %; 77.7 – 92.5 %), or 3 (48.4 %; 38.0 – 58.9 %). Conversely, higher sensitivity was obtained with criterion 3 (93.8 %; 90.4 – 96.3 %) than with criterion 2 (86.6 %; 82.2 – 90.3 %) or 1 (70.9 %; 65.3 – 76.0 %).
Conclusions To make a sufficiently specific diagnosis of HCC using gadoxetic acid-enhanced MRI based on typical enhancement features, washout should be determined on the PVP alone rather than combined with hypointensity on the TP or HBP.
Key points
- *Gadoxetic acid-enhanced MRI enhancement features can be used to diagnose HCC.*
- *Washout should be determined on the PVP alone for high specificity.*
- *Hypointensity on the TP or HBP increases sensitivity but lowers specificity.*

Keywords Hepatocellular carcinoma (HCC) · Gadoxetic acid (Gd-EOB-DTPA) · MRI · Liver · Diagnostic efficacy

Abbreviations

HCC	hepatocellular carcinoma
HAP	hepatic arterial phase
PVP	portal-venous phase
TP	transitional phase
HBP	hepatobiliary phase

I. Joo · J. M. Lee · D. H. Lee · J. H. Jeon · J. K. Han · B. I. Choi
Department of Radiology, Seoul National University Hospital, 101 Daehak-ro, Jongno-gu Seoul 110-744, Korea

I. Joo · J. M. Lee · D. H. Lee · J. H. Jeon · J. K. Han · B. I. Choi
Department of Radiology, Seoul National University College of Medicine, 103 Daehak-ro, Jongno-gu Seoul 110-799, Korea

J. M. Lee (✉) · J. K. Han · B. I. Choi
Institute of Radiation Medicine, Seoul National University Medical Research Center, 103 Daehak-ro, Jongno-gu Seoul 110-799, Korea
e-mail: jmsh@snu.ac.kr

Introduction

According to the current guidelines on the management of hepatocellular carcinoma (HCC), for hepatic nodules larger than 1 cm in patients with cirrhosis or chronic liver disease (CLD), HCC can be diagnosed without requirement of biopsy if the typical dynamic enhancement pattern, i.e., hypervascularity on the hepatic arterial phase (HAP) and washout on a later phase, is present in dynamic contrast-enhanced CT and/or MRI [1–5]. Recently, the accumulating evidence appears to suggest that MRI using hepatobiliary

Introdução

- Guidelines actuais: diagnóstico não invasivo de CHC em figado cirrótico se,
  - > 1cm
  - wash-in/wash-out
- Publicações actuais confirmam importancia do ácido gadoxético no diagnóstico
    - Contudo, não incluido nas actuais guidelines

Estado actual do EOB-DTPA na cirrose

- Vantagens
  - > sensibilidade detecção pequenos CHC
  - < FP (pseudo-lesões hipervasculares)
- Problemas
  - wash-out dificilmente apreciável
    - fase de transição (confusão com retenção HB)
  - significado dos nódulos hipointensos na fase HB

Objectivos

avaliar a capacidade da Gd-EOB DTPA MRI no diagnóstico não invasivo do CHC em cirrose

determinar a melhor fase do estudo dinâmico para reconhecer o wash-out em nódulos que apresentam wash-in

M&M

- Estudo retrospectivo
- Criterios de inclusão
  - cirrose
  - nodulos >1cm
  - diagnóstico final de CHC
- 387 nodulos/ 288 doentes
  - Child A=271; B=8; C=3
- Leitura por consenso (2 obs)

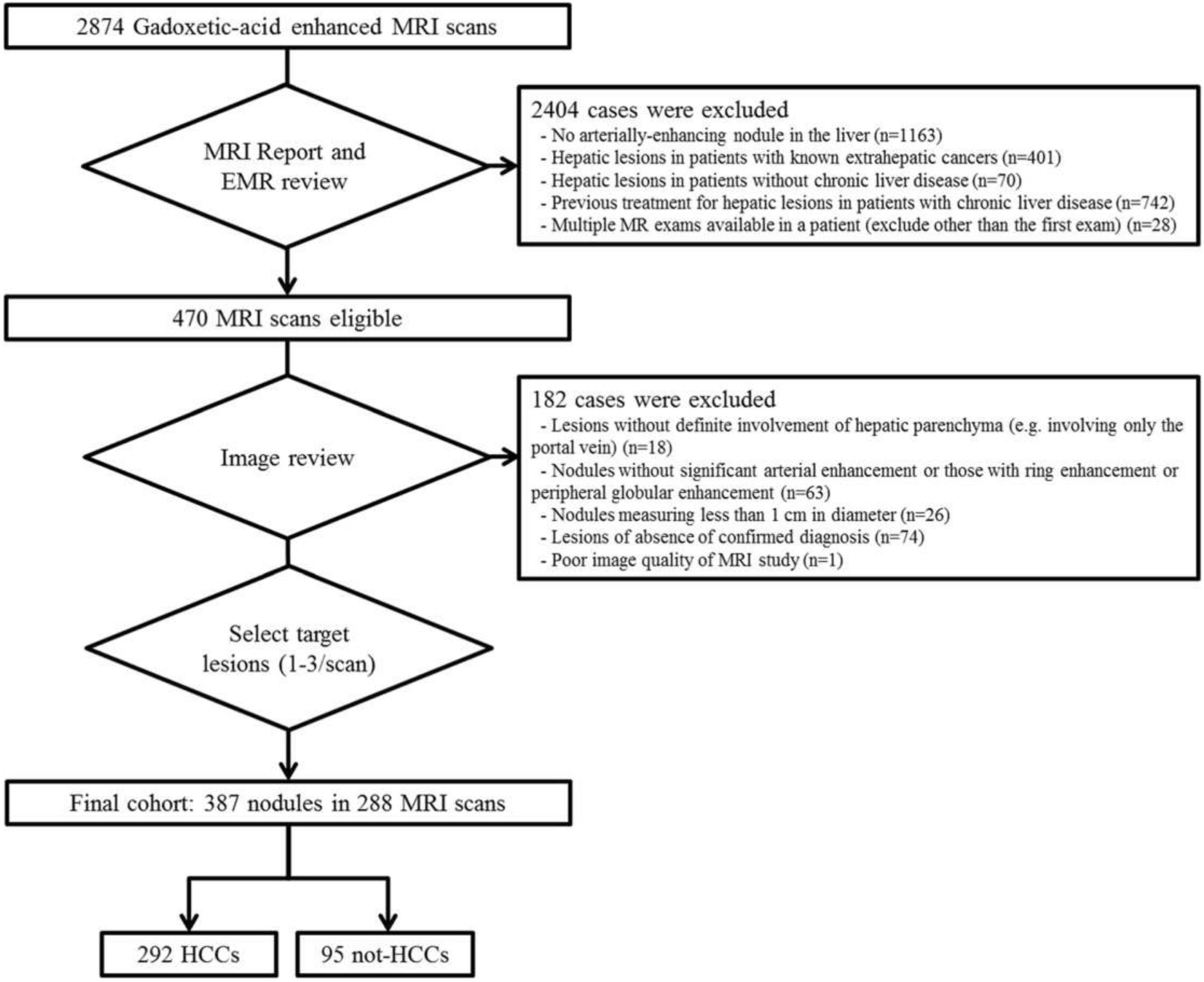
2874 Gadoxetic-acid enhanced MRI scans
MRI Report and EMR review
2404 cases were excluded
- No arterially-enhancing nodule in the liver (n=1163)
- Hepatic lesions in patients with known extrahepatic cancers (n=401)
- Hepatic lesions in patients without chronic liver disease (n=70)
- Previous treatment for hepatic lesions in patients with chronic liver disease (n=742)
- Multiple MR exams available in a patient (exclude other than the first exam) (n=28)
470 MRI scans eligible
Image review
182 cases were excluded
- Lesions without definite involvement of hepatic parenchyma (e.g. involving only the portal vein) (n=18)
- Nodules without significant arterial enhancement or those with ring enhancement or peripheral globular enhancement (n=63)
- Nodules measuring less than 1 cm in diameter (n=26)
- Lesions of absence of confirmed diagnosis (n=74)
- Poor image quality of MRI study (n=1)
Select target lesions (1-3/scan)
Final cohort: 387 nodules in 288 MRI scans
292 HCCs
95 not-HCCs

Teste de Referencia

- 292/387 nodulos diagnostico de CHC (35mm - 10-210mm)
  - histologia n=128
    - resecção n=115
    - biópsia percut= 13
  - critérios AASLD (TC previa - 2meses)
    - wash-in/wash-out n=164

- 95 nodulos não CHC (20mm; 10-125mm)
  - n=15 lesões malignas (histologia)
    - CHC/CCK;Mets
  - n=80 lesões benignas
    - histologia n=9
      - HNF, nodulo inlamatorio, shunt AP
    - imagem/FUP=71
      - hemangiomas
      - APS
      - nodulo inflamatorio

M&M

- Vários equipamentos 1,5-3T
- Injecção 10ml EOB-DTPA
- 1,5ml/s + bolus soro fisiol.
- 3D GRE T1 FS

Table 1 MR Acquisition parameters of the T1-weighted 3D GRE sequence at our institution

Acquisition Parameters	3.0 T scanner	1.5 T scanner
Repetition time (ms)	3.2 - 4.3	4.5 - 5.2
Echo time (ms)	2.0 - 3.0	2.2 - 2.5
Flip angle (°)	10 - 15	12
Section thickness (mm)	5.6 - 8.0 interpolated to 2.8 - 4.0	4.8 interpolated to 1.2
Fat suppression	Yes	Yes

M&M

- Análise estatística
  - Critério: wash-in (HAP) com wash-out fase posterior
    - Hipointensidade
      - PVP;
      - PVP+TP/HBP
  - S/E/VPP/VPN (95% CIs)
  - Acuidade

- RESULTADOS

DD dos nódulos hipervasculares na fase arterial

Table 2 Diagnostic Performances of Different Imaging Criteria for "Washout" on Gadoxetic Acid-Enhanced MRI for Hepatocellular Carcinoma

Imaging criteria	Sensitivity (%)	Specificity (%)	PPV (%)	NPV (%)	Accuracy (%)
Hyperenhancement on HAP					
+ Hypointensity on PVP	70.9 (207/292) [65.3-76.0]	97.9 (93/95) [92.6-99.7]	99.0 (207/209) [96.6-99.9]	52.2 (93/178) [44.6-59.8]	77.5 (300/387)
+ Hypointensity on PVP and/or TP	86.6 (253/292) [82.2-90.3]	86.3 (82/95) [77.7-92.5]	95.1 (253/266) [91.8-97.4]	67.8 (82/121) [58.7-76.0]	86.6 (335/387)
+ Hypointensity on PVP and/or TP, and/or HBP	93.8 (274/292) [90.4-96.3]	48.4 (46/95) [38.0-58.9]	84.8 (274/323) [80.4-88.6]	71.9 (46/64) [59.2-82.4]	82.7 (320/387)

Note: Numbers in parentheses were used to calculate percentages. Numbers in square brackets are 95 % confidence intervals. *HAP*=hepatic arterial phase, *PVP*=portal-venous phase, *TP*=transitional phase, *HBP*=hepatobiliary phase, *PPV*=positive predictive value, *NPV*=negative predictive value

- RESULTADOS

Sub-grupo de lesões confirmadas com histologia:
valor diagnóstico comparativo do sinal “wash-out”

Table 3 Diagnostic Performances of Different Imaging Criteria for “Washout” on Gadoxetic Acid-Enhanced MRI for Hepatocellular Carcinoma: Subgroup Analysis of Histopathologically Confirmed Lesions

Imaging criteria	Sensitivity (%)	Specificity (%)	PPV (%)	NPV (%)	Accuracy (%)
Hyperenhancement on HAP					
+ Hypointensity on PVP	72.7 (93/128) [64.1-80.2]	91.7 (22/24) [73.0-98.7]	97.9 (93/95) [92.6-99.7]	38.6 (22/57) [26.0-52.4]	75.7 (115/152)
+ Hypointensity on PVP and/or TP	82.8 (106/128) [75.1-88.9]	58.3 (14/24) [36.7-77.9]	91.4 (106/116) [84.7-95.8]	38.9 (14/36) [23.2-56.5]	78.9 (120/152)
+ Hypointensity on PVP and/or TP, and/or HBP	91.4 (117/128) [85.1-95.6]	33.3 (8/24) [15.7-55.3]	88.0 (117/133) [81.2-93.0]	42.1 (8/19) [20.3-66.5]	82.2 (125/152)

Note: Numbers in parentheses were used to calculate percentages. Numbers in square brackets are 95 % confidence intervals. *HAP*=hepatic arterial phase, *PVP*=portal-venous phase, *TP*=transitional phase, *HBP*=hepatobiliary phase, *PPV*=positive predictive value, *NPV*=negative predictive value

Discussão

- Diagnóstico de CHC (wash-in/wash-out qualquer fase)
  - WO FASE PORTAL >E (91%; VPP 97,9%)
  - Equivalente aos ECCM (WO PVP/DP - VPP 95%)
  - WO em fases mais tardias (TP;HBP) gera muitos FP
    - exclusão de CEUS pelas mesmas razões em 2010 das guidelines AASLD (>FP)

Limitações

- Estudo retrospectivo
- Gold standard imperfeito
- Ausência de comparação directa EOB-DTPA/ECCM
- Interpretação “isolada” sem outras sequências

Key points

- *Gadoxetic acid-enhanced MRI enhancement features can be used to diagnose HCC*
- *Washout should be determined on the PVP alone for high specificity.*
- *Hypointensity on the TP or HBP increases sensitivity but lowers specificity.*